IVUSS STANDARD FELINE ECHCOARDIOGRAPHIC PROTOCOL

General Guidelines

The protocol below includes all Required and Elective images and measurements. All Required images and measurements should be included in every case study that is submitted for review. Elective images and measurements should be included when deemed clinically appropriate and those situations are indicated in this protocol. The order of image collection is up to the echocardiographer. In addition to the Required and possible Elective images, modified views may be necessary to enhance visualization of pathology. Annotation of imaging planes and structures is not necessary.

The practical exam at the end of your certificate program will require you to obtain all Required and Elective images and measurements in a normal animal.

- Include in every echocardiographic case study:
  - A 3 second video of all Required imaging planes listed in this protocol
  - 3 second video of all Elective imaging planes required in specific clinical situations
  - Color flow Doppler of every valve, septa and PA bifurcation in every plane, diagnostic color may require adaptations of the imaging plane
  - A still frame of any color flow abnormalities
  - Still frames of Required measured images as indicated in the protocol
  - Still frames of all Elective measured images as indicated in this protocol
- LV measurements should be shown on 2D
  - 2D LV measurements only

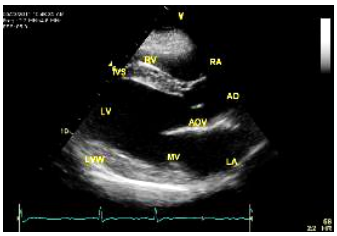

A technically correct rt 5Ch image:

- Long aorta
- Aortic valve seen with dash in the middle of aorta
- Good mitral valve motion
- Left ventricular wall and septum parallel to each other
- Horizontal on the sector – top wall of aorta similar depth to top of septum

Right Parasternal Echocardiographic Images

Five chamber (Inflow Outflow - IO)

- Measure any other areas of apparent hypertrophy in cats outside of the standard measuring locations
- M-mode of MV if done on inflow outflow view
  - look for SAM in cats

Oblique Pulmonary Artery View

- PW or CW of systolic PA flow
- Regurgitant flow velocity and PG if present and Aligned **(E - PH)**

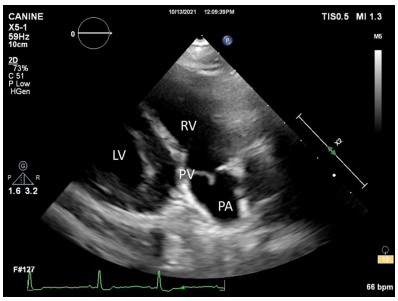

A technically correct oblique PA view:

- Clearly visible PV
- Good amount of main PA
- Aligned for a Doppler cursor

Four chamber

- M-mode mitral valve
  - look for SAM Measure
- measure other areas of apparent hypertrophy outside of the standard measuring locations
- 2D largest LA diameter at the end of ventricular systole, just before the mitral valve opens
- Measure smallest LA diameter, calculate LA fractional shortening
- TR velocity and PG if present and aligned

Short axis heart base pulmonary artery

- Measure MPA and Aortic diameters
  - calculate MPA/AO ratio
- M-mode or 2D measurements of largest and smallest RPA branch dimensions **(E – PAH)**
  - calculate PA distensibility
- Regurgitant flow velocity and PG if present and aligned **(E – PAH)**
- PW in RVOT
  - Measure RVOT velocity and PG (DRVOTO)

Short axis heart base LA/AO

- 2D - Swedish measurement
- M-mode of LA/AO calculate an LA fractional shortening

Short axis mitral valve

M-mode
  - Look for SAM

Short axis left ventricle – chordae tendinae

  - Measure septum, LV chamber and wall in diastole and LV chamber in systole
- 2D
  - Measure septum, LV chamber and wall in diastole and systole
  - Measure any other areas of apparent hypertrophy outside of the standard measuring locations

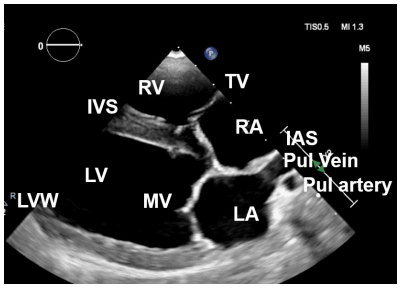

A technically correct 4Ch view:

- Good amount of RA in sector
- Clear inter-atrial septum (IAS)
- Pulmonary vein and right PA branch seen under the IAS
- Clear mitral valve motion
- Clear tricuspid valve motion
- Left ventricular wall and septum

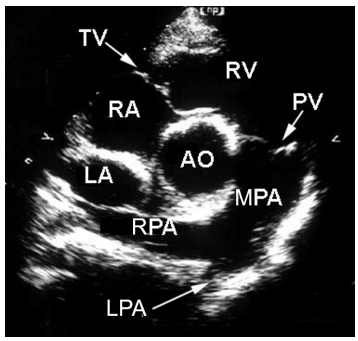

A technically correct short axis PA view :

- Distinct pulmonary valve motion
- Good PA bifurcation with RPA
- Circular and symmetrical aorta

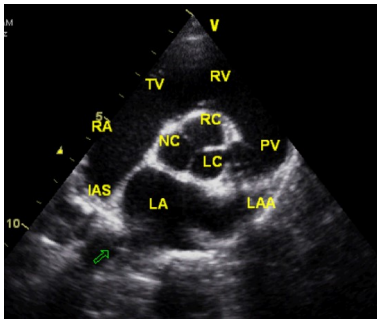

A technically correct LA/AO view:

- Clear inter-atrial septum
- Clear left auricle
- All 3 aortic valve cusps visible
- Completely closed circle and symmetrical aorta

Short axis left ventricle – papillary muscles

- Subjectively assess PM size

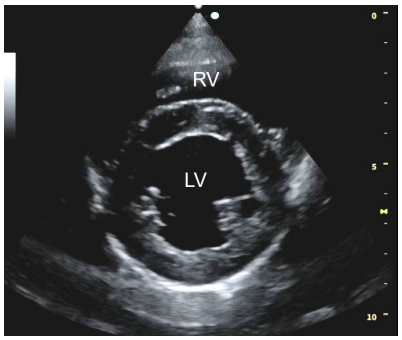

A technically correct CT view:

- Circular shape
- Distinct chordae – similar in size
- Minimal MV or papillary muscles
- Right ventricular chamber visible

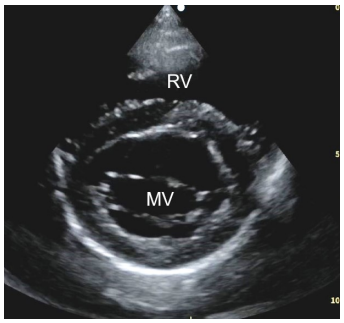

A technically correct MV view

- Symmetry - attachment similar at each side
- Both leaflets visible and moving well
- Right ventricular chamber visible

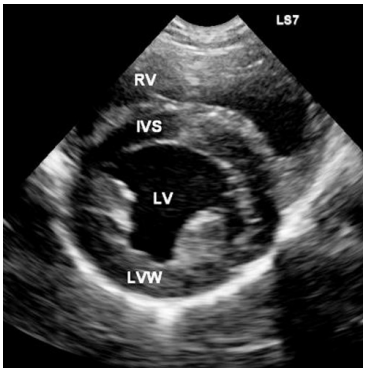

A technically correct PM view:

- Circular shape around the mushroom
- Papillary muscles – similar in size
- No MV or chordae seen
- Right ventricular chamber visible

Left Parasternal Echocardiographic Images

Left apical views

Four chamber

- PW mitral inflow
  - measurement of E and A wave velocities
  - this must be done on longest LV chamber
- CW Vmax measurement of MR regurgitant flow if present and aligned
  - a shorter LV chamber can be used for color and MR alignment
- CW or PW Vmax measurement of TV regurgitant flow if present and aligned
  - a shorter LV chamber can be used for color and TR alignment

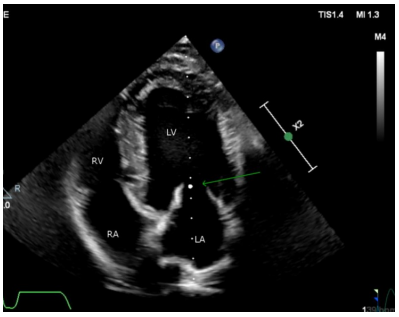

A technically correct 4CH view:

- A long LV (about 2x longer than width if normal)
- Vertically aligned for Doppler alignment of MV inflow and TDI
- a good RV and RA seen – RA slightly smaller or same size as LA

Five chamber

- PW above and below aortic valve
  - Vmax measured of each
- CW aortic valve
  - Vmax measurement
- CW of aortic regurgitant (AI) flow if present and more than mild and aligned **(E)**
  - measure Vmax and PHT
  - can be done on a foreshortened view if aligned better
- Obtain IVRT **(E)**
  - Measure time **(E)**
  - Calculate the E:IVRT **(E)**
  - Can be done on a foreshortened view
- CW Vmax measurement of MR if present
  - Can be done on a foreshortened view if color and alignment is better

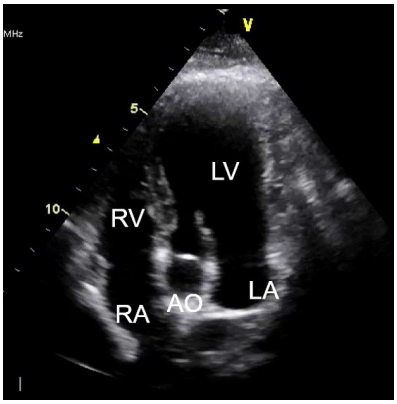

A technically correct 5CH view:

- A long LV (about 2x longer than width if normal)
- Vertically aligned for Doppler alignment of AO flow
- a good RV seen
- good MV motion

Left parasternal cranial long axis views

LVOT/Aorta/Aortic root

- This is the reference plane for the two other long axis view
  - A long almost horizontal aorta ensures the best right auricle

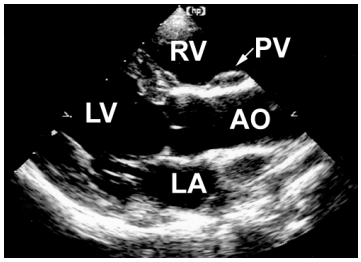

A technically correct left long axis aorta view:

- Along almost horizontal aorta
- Clear aortic valve and motion

RVOT/pulmonic valve/main pulmonary artery

- PW/CW Doppler if recordings were suboptimal on the right side or velocity was elevated or profile was abnormal

Tricuspid valve/right auricle/appendage

- PW or CW of tricuspid valve regurgitant flow if present and aligned **(E)**

Left parasternal cranial short axis view of the heart base

- Spectral Doppler of TR if present and aligned
- Spectral Doppler of PA systolic flow
- Spectral Doppler of PI if present and aligned **(E – PH)**

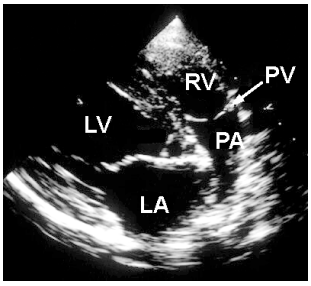

A technically correct left long axis PA view includes:

- A PA that is aligned for a Doppler cursor
- Good PV motion
- A clear LV, MV, etc not necessary

Left cranial left atrial appendage

- PW Doppler of auricular inflow and outflow
- Measure Vmax of each
- Look for “smoke”

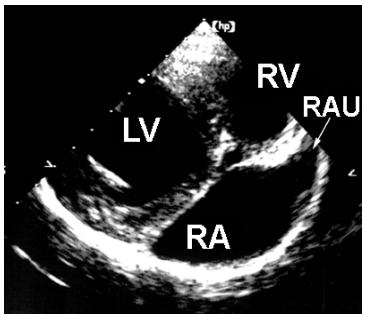

A technically correct left long axis RAA view:

- Clear right atrial appendage inside the sector
- Good TV motion for color (may need to adjust transducer at expense of auricle)

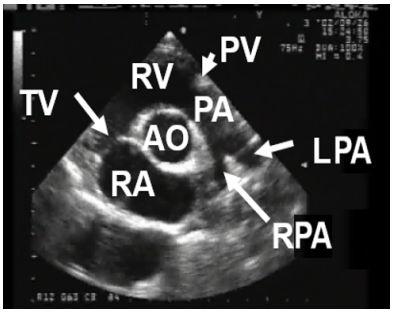

A technically correct left short axis view:

- Clear PV and PA with bifurcation
- Good TV motion
  - May need to fan cranial and caudal to bring each into view separately
- Round circular aorta
- This may need two slightly differing planes to obtain all components

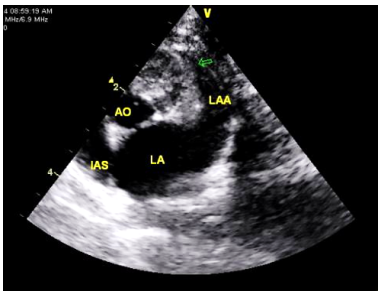

A technically correct left short axis LAA view:

- A clear appendage in the sector

REQUIRED – Feline 2D or M-mode Measurements

Echocardiographic Measurements
Septum - d
LV chamber - d
LV wall - d
Septum - s
LV chamber - s
LV wall - s
Fractional shortening
Max IVSd (2D long axis)
Max LVPWd (2D long axis)
Max IVSd (2D short axis)
Max LVPWd (2D short axis)
Heart rate
Left atrium (4ch)
Aorta (2D Swedish)
Left atrium (2D Swedish)
LA:AO (2D Swedish)
LA Max
LA Min
LA FS %

REQUIRED – Feline Doppler Measurements

Doppler Data
Ao flow Vmax
AO PG
RVOT flow Vmax
RVOT PG
PA flow Vmax
PA PG
MV E peak Vmax
MV A peak Vmax
MV E:A ratio
MV E dec time

ELECTIVE – Feline Doppler Measurements

TR Flow Vmax
TR PG
MR Flow Vmax
MR PG
IVRT
Left auricle Vmax

Appendix: Legend of Abbreviations

All abbreviations used in this protocol are listed below. Entries highlighted in yellow require committee clarification as their exact definitions are not explicitly stated in the source protocol.

Abbreviation	Full Term	Notes
AI	Aortic Insufficiency / Regurgitation	
AO	Aorta / Aortic	
AT	Acceleration Time	*Pulmonary artery flow timing*
CW	Continuous Wave Doppler	
CVD	Chronic Valvular Disease	
DCM	Dilated Cardiomyopathy	
E	Elective (protocol tag)	
EF	Ejection Fraction	
EPSS	E-Point Septal Separation	*M-mode measurement*
ET	Ejection Time	
IAS	Inter-Atrial Septum	
I/O	Inflow/Outflow	*Refers to five-chamber view*
IVRT	Isovolumic Relaxation Time	
LA	Left Atrium / Left Atrial	
LV	Left Ventricle / Left Ventricular	
LVIDd	LV Internal Dimension in Diastole	
LVIDdN	Normalized LVIDd	*Allometric scaling for body size*
LVOT	Left Ventricular Outflow Tract	
MPA	Main Pulmonary Artery	
MR	Mitral Regurgitation	
MV	Mitral Valve	
PA	Pulmonary Artery	
PAH	Pulmonary Arterial Hypertension	
PG	Pressure Gradient	
PH	Pulmonary Hypertension	
PHT	Pressure Half-Time	
PI	Pulmonic Insufficiency	
PM	Papillary Muscle(s)	
PV	Pulmonic Valve	
PW	Pulsed Wave Doppler	
RA	Right Atrium / Right Atrial	
RAA	Right Atrial Appendage	

Abbreviation	Full Term	Notes
RPAD	RPA Distensibility	*Calculated from RPA branch measurements*
RPA	Right Pulmonary Artery	
RT	Right-sided	*e.g. RT 5Ch = right parasternal five-chamber view*
RV	Right Ventricle / Right Ventricular	
RVOT	Right Ventricular Outflow Tract	
SAS	Subaortic Stenosis	
TAPSE	Tricuspid Annular Plane Systolic Excursion	
TDI	Tissue Doppler Imaging	
TR	Tricuspid Regurgitation	
TV	Tricuspid Valve	
Vmax	Maximum Velocity	